



COVID-19 (nCorona) Virus Outbreak Control and Prevention State Cell

Health & Family Welfare Department

Government of Kerala

Technical Guideline on diagnosis and treatment of COVID 19-associated mucormycosis (CAM)

No. 28/31/F2/2020 / H&FW- 16th May 2021

Since the onset of the COVID 19 pandemic there have been multiple reports across India of very high incidence of mucormycosis among patients with COVID 19 especially in those who are diabetic and those who have received steroids and immunosuppressants like Tocilizumab. Even though CAM has been reported from Kerala also over last 6 months, the number of cases reported is below the background rate of invasive mucormycosis reported in Immunocompromised especially those with uncontrolled diabetes in the preceding years. Since development of CAM is closely linked to glycemic status, a chapter on optimization of glycemic status in diabetic patients with concomitant COVID 19 infection has been incorporated into version 3 of Kerala State Guidelines on Treatment of Covid 19. A video module of the same has been prepared and circulated for IEC.

Covid-associated mucormycosis (CAM) is associated with high morbidity and mortality, exorbitant treatment costs and has led to shortage of antifungal drugs. Mucormycosis is a diabetes-defining illness, and remains as one of the most devastating complications in uncontrolled diabetics with mortality rates ranging between 40-80%. India contributes to 40% of the global burden of mucormycosis, with an estimated prevalence of 140 cases per million population. Single most risk factor for development of invasive mucormycosis is uncontrolled glycemic status. Studies have revealed that 47% of Indians are unaware of their diabetic status and only a quarter of diagnosed cases have achieved adequate glycemic control on treatment.

Pathogenesis of COVID 19-associated mucormycosis [CAM]

Unlike Covid associated pulmonary aspergillosis [CAPA], invasive mucormycosis has been observed even in patients with mild to moderate SARS- CoV-2 infections. The strongest predisposing factor appears to be hyperglycemia in undiagnosed or uncontrolled in patients with diabetes. Hyperglycemia leads to increased expression of the endothelial receptor GRP78, resulting in polymorphonuclear dysfunction, impaired chemotaxis and defective intracellular killing. An important virulence trait of Mucorales is the ability to acquire iron from the host which is an essential element for its growth. In conditions of ketoacidosis, free iron becomes readily available in the serum. This excess endogenous iron is efficiently taken up by the Mucorales through siderophores or iron permeases, further enhancing their virulence. These effects are greatly amplified by the use of corticosteroids and immunosuppressants in susceptible hosts. Corticosteroids themselves cause impairment in the neutrophil migration, ingestion, and phagolysosome fusion. Coupled with the potential implications of steroid-induced hyperglycemia, the COVID 19 patients with diabetes receiving corticosteroids or other immunosuppressants are exceptionally vulnerable to the development of mucormycosis.

When and how to suspect CAM

CAM –can occur along with active COVID 19 infection [concomitant] and can occur sequentially in weeks or months following recovery [sequential]

CAM based on clinical presentation is classified as

1. Rhino-orbito-cerebral mucormycosis [ROCM]
2. Pulmonary mucormycosis.
3. Gastrointestinal mucormycosis –rarely seen in neonates.
4. Disseminated mucormycosis-seen in the setting of diabetic ketoacidosis or severe immunosuppression.
5. Primary cutaneous mucormycosis

Common presentation of ROCM

- Initially – nasal blockade or congestion, nasal discharge (bloody or brown/ black), local pain
- Facial pain or numbness or swelling, palpebral swelling, conjunctival congestion, ptosis, extraocular muscle involvement.
- Headache, orbital pain, loss of vision
- Toothache, loosening of maxillary teeth, jaw involvement
- Blurred or double vision with pain; paresthesia, fever, skin lesion, thrombosis & necrosis

Warning symptoms and signs of Rhino-orbito-cerebral mucormycosis

- Nasal stuffiness
- Foul smell
- Epistaxis
- Nasal discharge - mucoid, purulent, blood-tinged or black
- Nasal mucosal erythema, inflammation, purple or blue discoloration, white ulcer, ischemia, or eschar
- Eyelid, periocular or facial edema
- Eyelid, periocular, facial discoloration
- Regional pain – orbit, paranasal sinus or dental pain
- Facial pain
- Worsening headache
- Proptosis
- Sudden loss of vision
- Facial paresthesia, anesthesia
- Sudden Ptosis
- Ocular motility restriction, diplopia
- Facial palsy
- Fever, altered sensorium, paralysis, focal seizures

Pulmonary mucormycosis:

- Fever, cough, chest pain, pleural effusion, hemoptysis, worsening of respiratory symptoms
- Lung CT – suspect mucormycosis in patients with thick-walled lung cavity (need to differentiate from covid-associated pulmonary aspergillosis), reverse halo sign, multiple nodules, pleural effusion .Presence of reverse halo sign [Atoll sign],more than 10 pulmonary nodules and pleural effusion is more in favour of CAM than CAPA. Presence of bronchial thickening, tracheobronchial involvement, peribronchial collection and tree in bud nodules are more in favour of CAPA.Tuberculosis has to be ruled out by appropriate tests.

Rhino-orbito-cerebral

- Consult ENT surgeon for endoscopic collection of debrided tissue/biopsy – one portion in sterile saline for microscopy & culture, other portion in formalin saline for histopathology

Pulmonary

- Broncho-alveolar lavage (BAL), Mini BAL, non-bronchoscopic lavage, transbronchial biopsy, CT guided biopsy from lung – process for microscopy & culture

How to diagnose mucormycosis

Mucormycosis is a medical emergency and in correct context should be started on empirical therapy even prior to diagnostic confirmation.

Suspected patients should undergo appropriate radio-imaging study at the earliest. MRI - PNS with brain contrast study for ROCM and plain CT thorax for pulmonary mucormycosis must be done. Diagnosis is confirmed by fungal staining /culture from appropriately collected specimens.

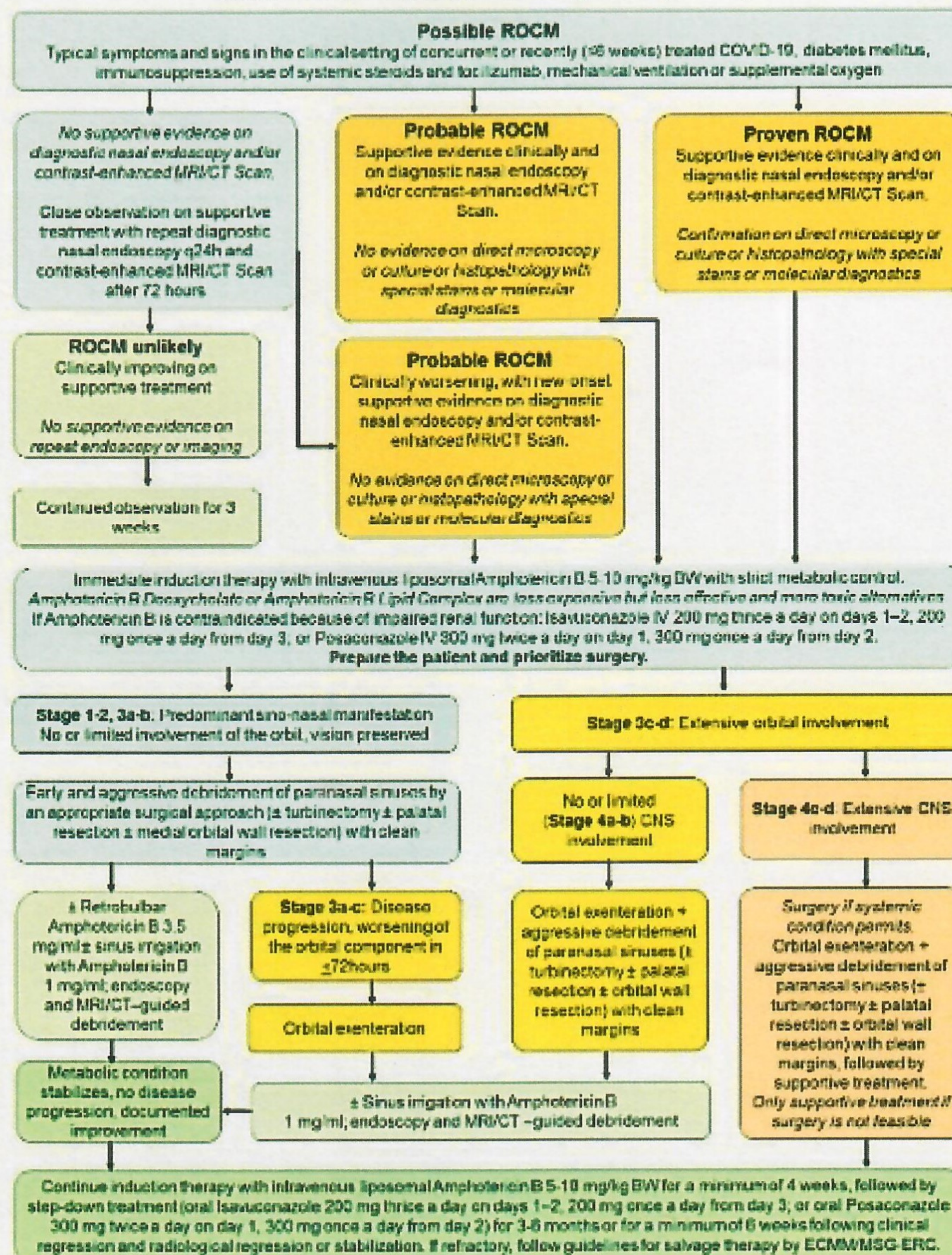
Treatment of CAM

Team approach is required with Physician, infectious disease specialist, microbiologist, histopathologist, intensivist, neurologist, ENT specialist, ophthalmologist, dentist, surgeons, radiologists etc.

1. Control of diabetes & diabetic ketoacidosis
2. Reduce steroids (if patient is still on) with aim to discontinue rapidly
3. Discontinue other immunomodulating drugs if patient is taking like: Baricitinib, Tofacitinib
4. Surgical debridement: Extensive surgical debridement must be done to remove all necrotic material. Antifungal penetration into necrotic tissue is sub-optimal. Involved eye may have to be exenterated as per opinion of ophthalmologist.
5. Medical treatment
 - a. Insert peripherally inserted central catheter (PICC line) or central venous catheter
 - b. Maintain adequate systemic hydration, infuse normal saline IV before amphotericin B infusion
 - c. Antifungal therapy
 - i. Liposomal amphotericin B (L-AmB) (preferred treatment) 5mg/kg/day, dilute in 200 cc 5% dextrose over 2-3 hours infusion (avoid slow escalation; higher dose 10mg/Kg/day may be given in brain involvement)
 - ii. Amphotericin B deoxycholate (D-AmB): only if cost and availability of L-AmB is an issue; 1mg/kg/day in 5% dextrose, slow infusion for 6-8 hours at rate of 0.08 mg/kg/hour. Pre-medication may be required to avoid infusion reaction. Pre-loading with 1 L NS in patients without risk of fluid overload, and administering 1L NS after infusing Amphotericin will help in limiting nephrotoxicity.
 - iii. Monitor renal function & potassium level while treating with amphotericin B. If hypokalemia is not getting corrected with intravenous potassium chloride, hypomagnesemia should be ruled out.

- iv. Patients who are intolerant to amphotericin B, alternative agents are posaconazole or isavuconazole (injection/tablets) .Posaconazole is also available as syrup formulation.
 - v. Tab/intravenousposaconazole: 300mg twice a day on first day, followed by 300mg once a day. Check posaconazole trough level after 7 days of therapy [if TDM-Therapeutic drug monitoring is available] & check for drug interaction.
 - vi. Tab/intravenousisavuconazole: 200mg three time a day for two days, followed by 200 mg once a day.
6. Monitor patients clinically,microbiologically and with radio-imaging for response / disease progression.
7. After 3-6 weeks of amphotericin B therapy, consolidation therapy with (posaconazole/isavuconazole) for 3-6 months should be instituted. Duration of therapy depends on clinical response and radiological resolution and has to be individualized.

Management Approach for Possible, Probable or Proven Rhino-Orbito-Cerebral Mucormycosis (ROCM)



How to prevent COVID associated Mucormycosis

- As poorly controlled diabetes is the major issue, good glycaemic control during management of COVID 19 patients is required. [Refer Optimization of Glycaemic status in patients with diabetes and COVID 19: Chapter 13: Kerala State COVID 19 treatment guidelines Version 3]
- Systemic /oral steroids should be administered only as per indications mentioned in: Kerala State COVID 19 treatment guidelines Version 3.
- Glycaemic control should be optimized in all patients especially when started on steroids.
- In all patients with diabetes, best way to prevent CAM is by optimizing glycaemic status as cases of CAM have been reported even without exposure to steroids.

- All patients at risk of developing mucormycosis those with uncontrolled diabetes mellitus, chemotherapy, post-transplant, long term steroids and those with COVID 19 moderate to severe disease should ideally avoid construction sites. As air near construction sites will be full of fungal spores and the Immunocompromised are at risk of developing COVID associated pulmonary aspergillosis [CAPA] and CAM.
- Universal masking reduce exposure to Mucorales and hence should be strictly practiced.
- Strict aseptic precautions while administering oxygen must be adhered to like sterile water for humidifier, daily change of sterilized humidifier and the tubes].
- During discharge of the patients, advice about the early symptoms or signs of mucormycosis (facial pain, nasal blockage and excessive discharge, loosening of teeth etc., chest pain, respiratory insufficiency) and to report to the treatment facility.
- Aeromycological study to assess the presence and to quantify Fungal spore count should be done periodically in all ICUs.

Misinformation

1. Mucorales are not black fungi. Black fungi are different category of fungi having melanin in the cell wall.
2. Mucormycosis is not contagious. It does not spread from one person to another.
3. Mucormycosis is not spread by oxygenation, humidifier, and water. The fungi remain in the indoor & outdoor environment. The spores enter the respiratory tract via air.
4. No antifungal prophylaxis is recommended as the incidence is not more than

ACTION POINTS

1. Fungal spore count should be done in all ICUs in Kerala at the earliest.
2. Cases of CAM in any hospital should be reported to Kerala State Medical Board by email [ksmbhealth@gmail.com] on a real time basis to understand the actual situation

in Kerala. Details of all cases of CAM reported from Jan 2021 must be shared to this email id for understanding the situation in Kerala and for further planning.


Principal Secretary

References

1. RECOVERY Collaborative Group. Dexamethasone in Hospitalized Patients with Covid-19. N Engl J Med. 2021 Feb 25;384(8)
2. WHO Rapid Evidence Appraisal for COVID-19 Therapies (REACT) Working Group Association Between Administration of Systemic Corticosteroids and Mortality Among Critically Ill Patients With COVID-19: A Meta-analysis. JAMA. 2020 Oct 6;324(13):1330-1341
3. [https://www.mohfw.gov.in/pdf/Clinical Guidance on DiabetesManagementatCOVID19PatientManagement Facility.pdf](https://www.mohfw.gov.in/pdf/Clinical%20Guidance%20on%20Diabetes%20Management%20at%20COVID-19%20Patient%20Management%20Facility.pdf)
4. Global guideline for the diagnosis & management of mucormycosis. Lancet Infect Dis 2019; 19: e405-e421
5. Honavar SG. Rhino-orbito-cerebral mucormycosis – Guidelines for diagnosis, staging, and management. Indian J Ophthalmol 2021;69:XX-XX